



A 31-Year-Old Male with Progressive Blurry Vision

Wendy Shieh, MD; Nicholas E. Engelbrecht, MD



Introduction:

A 31-year old male with no past ocular history presented with a blurred spot centrally in his left eye that had never occurred before. Past medical history is only significant for seasonal allergies and no recent illness, trauma, or foreign travel was reported. A complete review of systems and social history query were unremarkable.

Examination:

The patient's visual acuity was 20/20 in the right eye and 20/100 in the left eye. Pupillary exam did not reveal an afferent pupillary defect in either eye and intraocular pressures were within normal limits. Slit-lamp examination showed a normal anterior segment exam bilaterally. Dilated fundus exam of the left eye showed two yellowish macular lesions with indistinct borders suggestive of chorioretinitis, although there was a lack of overlying vitritis or associated hemorrhage (Figure 1). Peripheral examination did not reveal findings of vasculitis or other abnormalities. The right eye fundus exam was completely normal.

Initial fluorescein angiography of the left eye demonstrated early blockage corresponding with the clinically observed lesions while later phases demonstrated hyperfluorescence consistent with staining in the same areas (Figure 2). Disruption of the ellipsoid zone and underlying retinal pigmented epithelium is seen on optical coherence tomography of (Figure 3). Due to these findings, a systemic work-up including CBC, RPR, FTA-ABS, Quantiferon Gold, toxoplasmosis IgG and IgM titers, ACE, and chest x-ray were pursued, all of which yielded normal results.

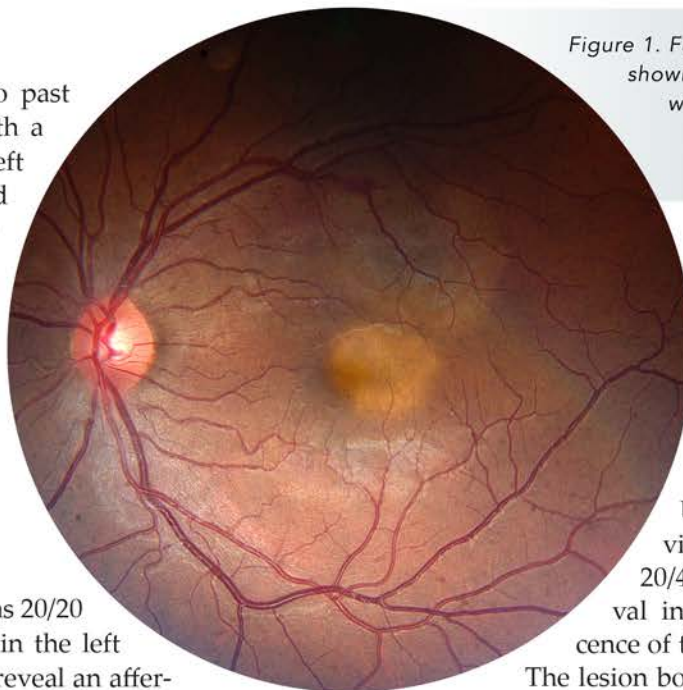


Figure 1. Fundus photograph of the left eye showing two yellowish macular lesions with indistinct borders but without evidence of overlying vitritis or associated hemorrhage.

One week later, the macular lesions appeared less active on fundus exam and the patient was instructed to complete a Medrol dose pack course which was initiated after a negative work-up for infectious etiologies. Upon follow-up 2 weeks later, visual acuity had decreased to 20/400 in the left eye and an interval increase in size due to coalescence of the macular lesions was noted.

The lesion borders were now more defined by finger-like projections that are consistent with macular serpiginous choroiditis (Figure 4). Consequently, an increase of oral prednisone. Fortunately, the right eye has not shown any active lesions and visual acuity remains at 20/20.

Discussion:

Serpiginous choroiditis is a rare and progressive condition involving inflammation of the retinal pigment epithelium, choriocapillaris, and choroid that often has bilateral involvement.¹ The disease affects young to middle-aged adults with epidemiologic studies demonstrating greater prevalence in men compared to women and generally no systemic associations.²

Clinically, serpiginous chroiditis initially presents with central vision loss, metamorphopsia or a scotoma in one eye with later involvement of the fellow eye. Approximately 80% of reported serpiginous choroiditis cases are of the peripapillary geographic type, where the lesions begin as poorly-defined grayish or creamy yellow sub-retinal infiltrates in the peripapillary region

and progress centrifugally with a serpentine appearance.² Compared with classic serpiginous choroiditis, macular serpiginous choroiditis carries a poorer visual prognosis due to early foveal involvement and higher risk for secondary choroidal neovascularization (CNV).³ On fluorescein angiography, active lesions show early hypofluorescence with hyperfluorescent

borders while later phases will reveal hyperfluorescence and staining. These angiographic features may help differentiate macular serpiginous choroiditis from other entities that can closely mimic its clinical appearance such as age-related macular degeneration, idiopathic subretinal neovascularization, atypical or chronic central serous retinopathy.

The mainstay of treatment for macular serpiginous choroiditis largely consists of oral or periocular steroids. Immunosuppressive therapy including cyclosporine A, cyclophosphamide, or a combination of azathioprine, cyclosporine, and prednisone have been

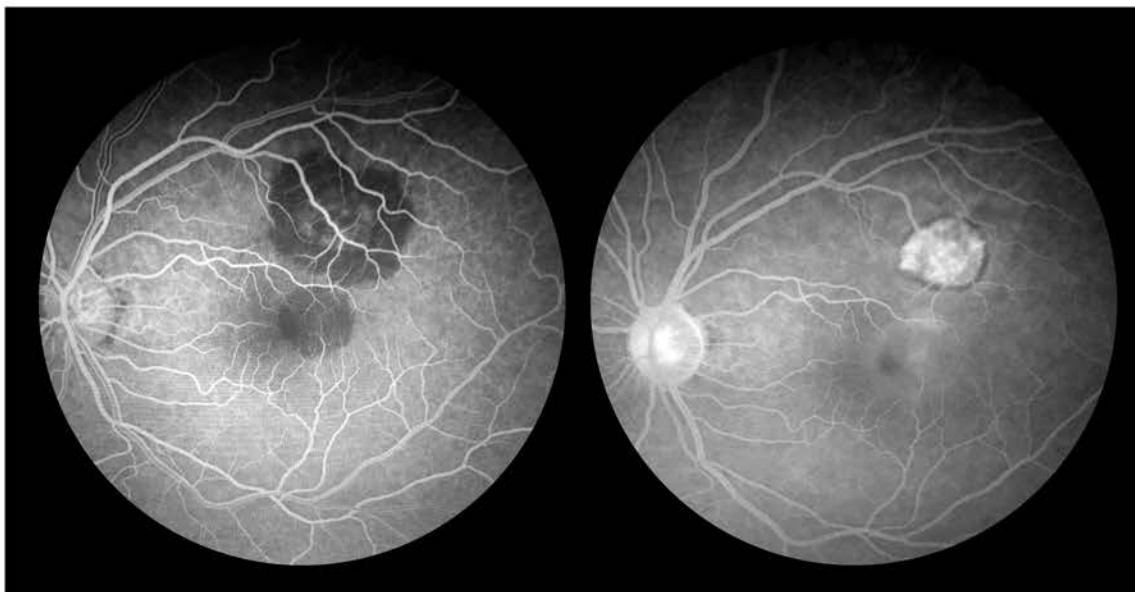

Figure 2. (A) Fluorescein angiography of the left eye demonstrating early blockage corresponding with the clinically observed lesions while later phases (B) show hyperfluorescence consistent with staining in the same areas.

reported in small case series to achieve remission of active disease.^{4,6} Venkatesh et al. demonstrated that pulsed intravenous cyclophosphamide therapy for 3 days followed by a 6-month oral steroid taper was efficacious in rapid resolution of acute macular serpiginous choroiditis lesions and thus preservation of good functional acuity.⁷ In a follow-up prospective, randomized study, the authors compared the efficacy of pulsed dexamethasone, pulsed cyclophosphamide, and a combination of both, each administered for 3 days in patients with active serpiginous choroiditis lesions involving or threatening macula. Although the treatment group receiving pulsed cyclophosphamide showed faster

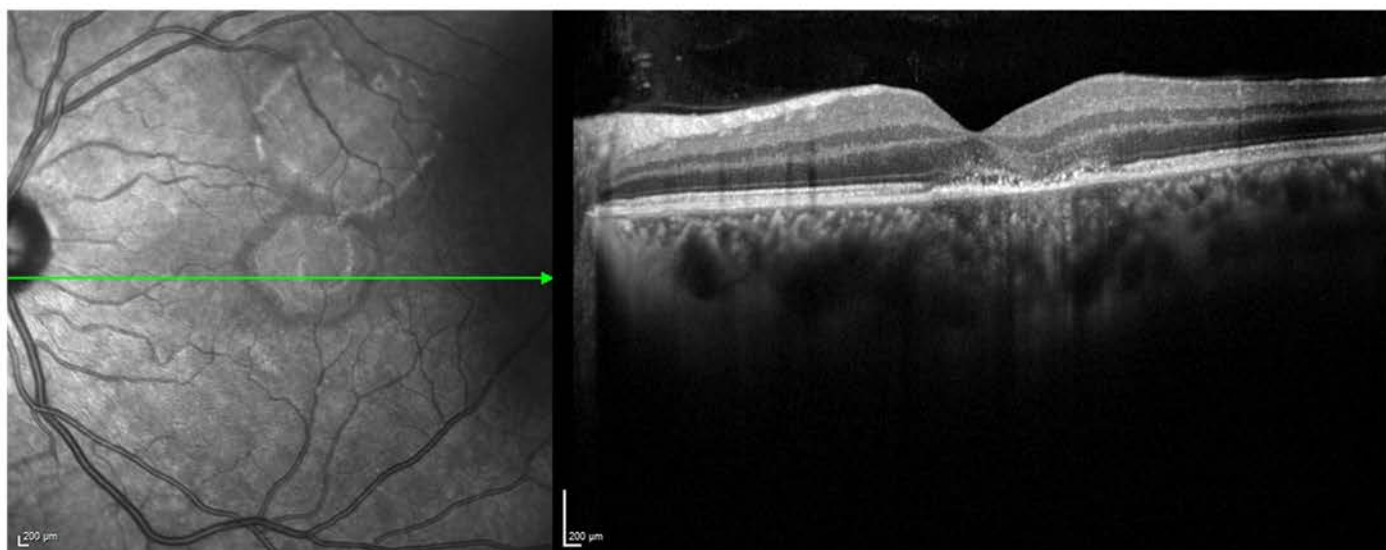


Figure 3. Disruption of the ellipsoid zone and underlying retinal pigmented epithelium on OCT imaging through areas of suspected choroiditis.

healing of lesions, there was ultimately no difference in gained visual acuity between all three groups.⁸

Recently, Weiss et al. reported a case of long-standing serpiginous choroidopathy treated with bone marrow derived stem cells (BMSC) under the Stem Cell Ophthalmology Treatment Study (SCOTS). After 8 months of retrobulbar, subtenon, intravitreal and intravenous injections of BMSC, improvement in visual acuity and an increase in macular volume on OCT were observed.⁹ While further investigation is warranted, these results suggest that the use of BMSC as provided in SCOTS may be a potential therapeutic approach in serpiginous choroiditis and other related entities.

References:

1. Sahu DK, Rawoof A, Sujatha B. Macular serpiginous choroiditis. *Indian J Ophthalmol.* 2002 Sep;50(3):189–96.
2. Lim W-K, Buggage RR, Nussenblatt RB. Serpiginous choroiditis. *Surv Ophthalmol.* 2005 Jun;50(3):231–44.
3. Mansour AM, Jampol LM, Packo KH, Hrisomalos NF. Macular serpiginous choroiditis. *Retina Phila Pa.* 1988;8(2):125–31.
4. Secchi AG, Tognon MS, Maselli C. Cyclosporine-A in the treatment of serpiginous choroiditis. *Int Ophthalmol.* 1990 Oct;14(5–6):395–9.
5. Akpek EK, Jabs DA, Tessler HH, Joondeph BC, Foster

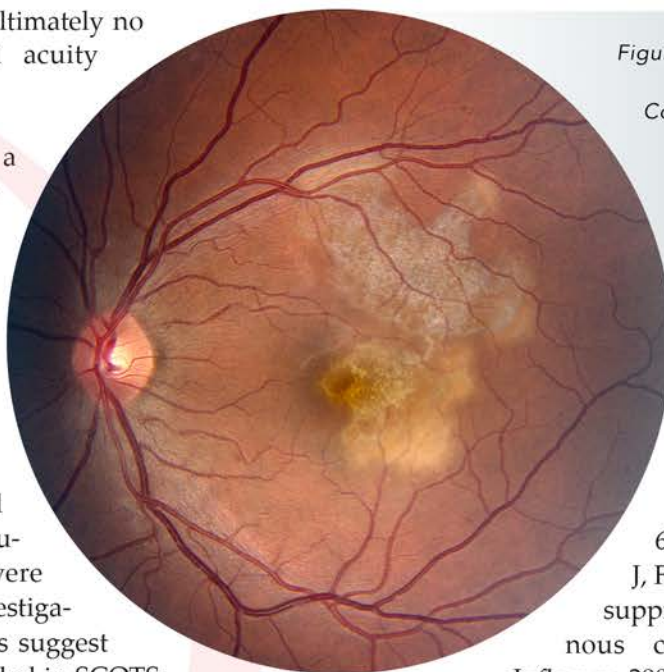


Figure 4. Fundus photograph of the left eye at 2-week follow up. Coalescence of the active lesions and finger-like appearance of lesion borders suggest a diagnosis consistent with macular serpiginous choroiditis.

CS. Successful treatment of serpiginous choroiditis with alkylating agents. *Ophthalmology.* 2002 Aug;109(8):1506–13.

6. Akpek EK, Baltatzis S, Yang J, Foster CS. Long-term immunosuppressive treatment of serpiginous choroiditis. *Ocul Immunol Inflamm.* 2001 Sep;9(3):153–67.

7. Venkatesh P, Gogia V, Gupta S, Tayade A, Shilpy N, Shah BM, et al. Pulse cyclophosphamide therapy in the management of patients with macular serpiginous choroidopathy. *Indian J Ophthalmol.* 2015 Apr;63(4):318–22.

8. Venkatesh P, Tayade A, Gogia V, Gupta S, Shah BM, Vohra R. Short-term Intensive Immunosuppression: A Randomized, Three-arm Study of Intravenous Pulse Methylprednisolone and Cyclophosphamide in Macular Serpiginous Choroiditis. *Ocul Immunol Inflamm.* 2016 Nov 16;0(0):1–8.

9. Weiss JN, Benes SC, Levy S. Stem Cell Ophthalmology Treatment Study (SCOTS): improvement in serpiginous choroidopathy following autologous bone marrow derived stem cell treatment. *Neural Regen Res.* 2016 Sep;11(9):1512–6.

Midwest Ophthalmologic Symposium September 9, 2017

Visit tri-stl.com for a Registration Form
or contact Kelly at kelly.mckittrick@rc-stl.com
314-367-1181 x-2157, for more information.



THE RETINA INSTITUTE
(314) 367-1181
tri-stl.com

Kevin J. Blinder, MD
Nicholas E. Engelbrecht, MD
M. Gilbert Grand, MD

Daniel P. Joseph, MD, PhD
Thomas K. Krummenacher, MD
Richard J. Rothman, MD

Gaurav K. Shah, MD
Bradley T. Smith, MD
Matthew A. Thomas, MD