



A 44-Year-Old Woman with Unilateral Blurry Vision

Wendy Shieh, MD; Sabin Dang, MD; Gaurav K. Shah, MD



Introduction:

A 44-year-old woman with no past ocular history presented with centrally blurred vision in the right eye for 1-week duration. Her medical history is only significant for hypothyroid that is well-controlled with levothyroxine. A complete review of systems and social history query were unremarkable.

Examination:

The patient's best-corrected visual acuity (BCVA) was finger counting in the right eye and 20/20 in the left eye. Pupillary exam did not reveal an afferent pupillary defect and intraocular pressures were within normal limits. Slit-lamp examination showed a normal anterior segment exam bilaterally. Dilated fundus exam of the right eye showed optic nerve edema and lipid exudation within the macula in radially oriented fashion (Figure 1). There was no evidence of vitreous inflammation or vasculitic changes of the retinal vessels. No abnormalities were noted in the left eye.

Fluorescein angiography of the right eye demonstrated hyperfluorescence of the optic nerve but no vascular staining or occlusion (Figure 2A). The clinical findings of macular edema with associated exudation in the outer plexiform layer as well as the presence of subretinal fluid were illustrated by optical coherence tomography (OCT) and enface OCT as shown in Figure 2B and Figure 3, respectively. OCT-angiography (OCTA) demonstrates capillary dropout within the superficial plexus, while deeper retinal layers demonstrated shadowing of flow signal due to the presence of lipid exudate at the level of the deep plexus (Figure 3).

Given the constellation of findings and the patient

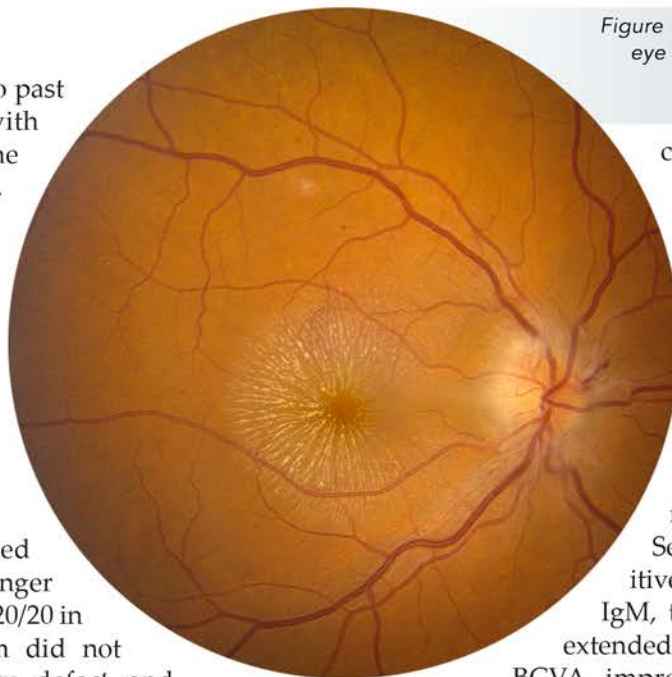


Figure 1. Fundus photograph of the right eye showing optic nerve edema and a lipid exudation pattern consistent with a macular star.

confirming ownership of a domestic cat, empiric treatment with doxycycline 100mg twice daily was initiated due to a presumptive diagnosis of neuroretinitis caused by *Bartonella henselae*. Upon follow-up 2 weeks later, BCVA in the right eye had improved to 20/70 with decreased fluid noted on OCT imaging.

Serology work-up revealed positive titers for *Bartonella* IgG and IgM, thus doxycycline therapy was extended for 2 additional weeks. The BCVA improved further to 20/50 at 2 months, with OCT showing residual exudate but complete resolution of subretinal fluid (Figure 4).

Discussion:

Cat-scratch disease (CSD) is a self-limited, systemic condition caused by the gram-negative organism *Bartonella henselae*. Ophthalmic manifestations can occur in 5-10% of patients with CSD and include Parinaud oculoglandular syndrome, neuroretinitis, and focal retinochoroiditis.¹ Parinaud oculoglandular syndrome presents with follicular conjunctivitis associated with regional lymphadenopathy (preauricular, submandibular, or cervical) and fever. Neuroretinitis in CSD is characterized by unilateral disc edema and a partial or complete macular star. Consequently, patients can develop mild to severe unilateral or bilateral visual loss, macular serous detachment, and central scotoma. Similarly, small areas of focal choroiditis have been reported and are often associated with exudative retinal detachments.²

The clinical appearance of a macular star is caused by

leakage of lipid exudates in the outer plexiform layer, lending to the stellate pattern around the fovea after the serum is absorbed. Chi et al. characterized 53 patients with CSD optic neuropathy, of which 17% had bilateral involvement and neuroretinitis was found in in 45% of eyes. The authors concluded that optic neuropathy related to CSD has a favorable visual prognosis, especially with good visual acuity at presentation. No association was noted between final visual acuity and the use of systemic antibiotic or steroids.³

Despite the infectious nature of CSD, some controversy exists regarding treatment guidelines since the disease can resolve without treatment in immunocompetent patients. However, dramatic in vivo responses to erythromycin or doxycycline in immunocompromised patients have led to the recommendation that either antibiotic can be used treat all patients with severe ocular or systemic complications of *B. henselae* infection.⁴ Doxycycline (100 mg given orally twice daily) is

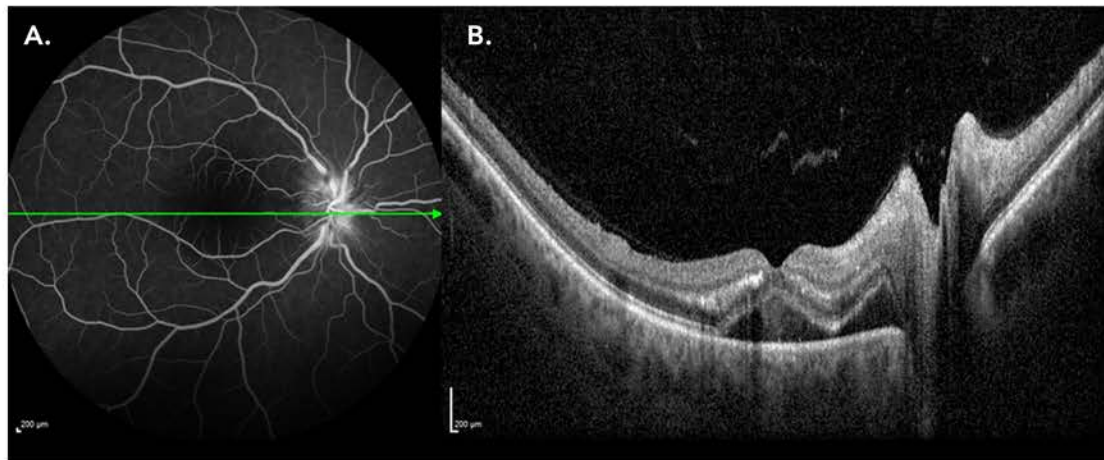


Figure 2. (A) Fluorescein angiography of the right eye showing hyperfluorescence of the optic nerve without evidence of occlusive disease or vasculitis. (B) OCT imaging illustrating macular edema with associated exudation in the outer plexiform layer and subretinal fluid.

preferred due to its superior intraocular and central nervous system and can be administered intravenously or with rifampin (300 mg orally twice daily) for more severe disease. Treatment duration is typically 2 to 4 weeks in immunocompetent patients and at least 4 months for immunocompromised patients.¹

Recently, Pichi et al. reported a case of OCTA-confirmed neovascularization associated with CSD neuroretinitis in the absence of retinal vascular occlusion.⁵ The authors suggest that *B.henselae* infection may lead to angioproliferative lesions driven by vascular endothelial growth factor or migration factor produced by either the organism or colonized vascular endothelial

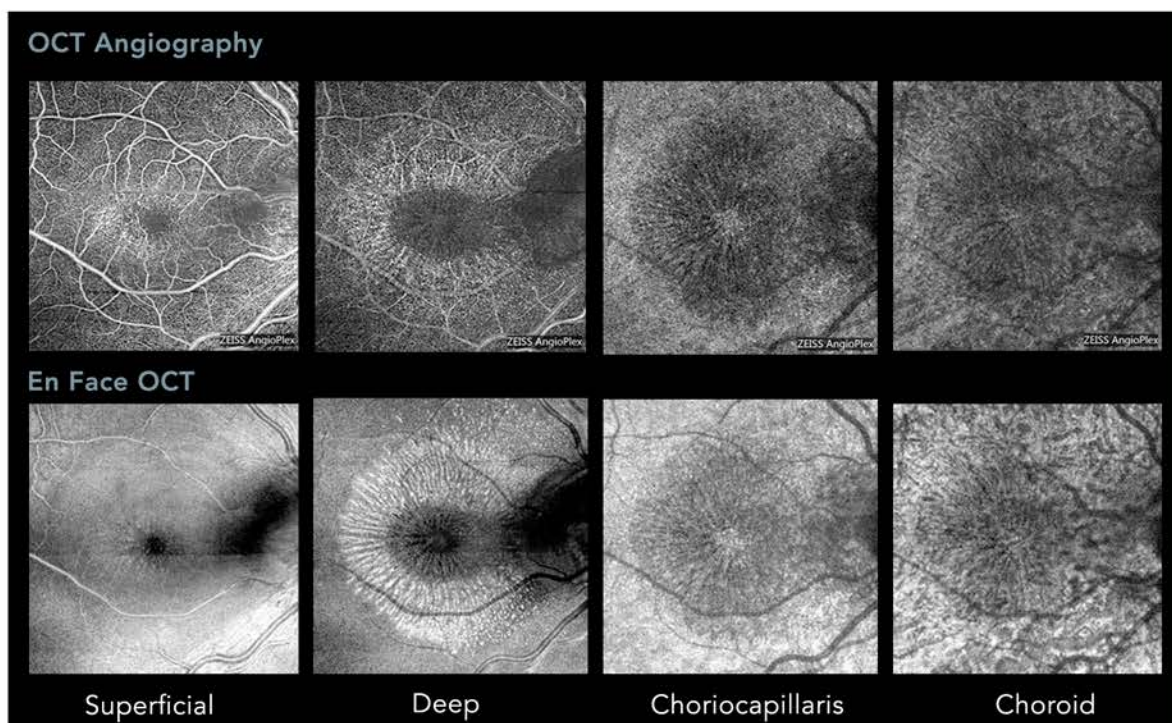


Figure 3. OCT Angiography (top row) showing capillary dropout within the superficial plexus and shadowing of flow signal in deeper retinal layers due to lipid exudation at the level of the deep plexus. En face OCT imaging (bottom row) showing hyperreflectivity in the deep retinal layers corresponding to exudate as well as hyporeflectivity where subretinal fluid is present.

cells. Other studies have also described Bartonella-related pathological angiogenesis resulting in choroidal neovascularization of the optic disc or within the macula. Although our patient currently does not have a focus of neovascularization, OCTA may be a fast, non-invasive modality for surveillance of this potential complication.

References:

1. Cunningham ET Jr, Koehler JE. Ocular bartonellosis. *Am J Ophthalmol.* 2000;130(3):340-349.
2. Ormerod LD, Dailey JP. Ocular manifestations of cat-scratch disease. *Curr Opin Ophthalmol.* 1999 Jun;10(3):209-16.
3. Chi SL, Stinnett S, Eggenberger E, et al. Clinical characteristics in 53 patients with cat scratch optic neuropathy. *Ophthalmology.* 2012 Jan;119(1):183-7.
4. Koehler JE, Relman DA. Bartonella species. In: Yu

WL, Merigan TC Jr, Barriere SL, editors. Antimicrobial therapy and vaccines. Baltimore: Williams and Wilkins, 1999:578– 583.

5. Pichi F, Srivastava SK, Levinson A. A Focal Chorioretinal Bartonella Lesion Analyzed by Optical Coherence Tomography Angiography. *Ophthalmic Surg Lasers Imaging Retina.* 2016 Jun 1;47(6):585-8.

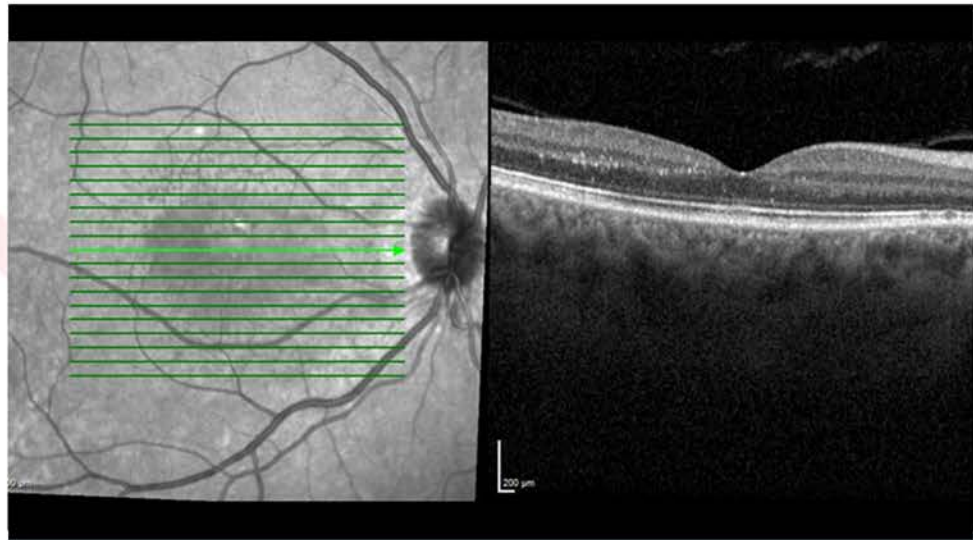


Figure 4. OCT showing residual exudates but complete resolution of subretinal fluid at 2-month follow-up.

